ResearchGate

See discussions, stats, and author profiles for this publication at: https://www.researchgate.net/publication/340749746

Histological comparison of Platelet rich fibrin clots prepared by fixed-angle versus horizontal centrifugation

Article *in* Platelets · April 2020

DOI: 10.1080/09537104.2020.1754382

CITATIONS
59

READS
2,596

7 authors, including:

Masako Fujioka-Kobayashi
Shimane University
116 PUBLICATIONS **4,590** CITATIONS

SEE PROFILE

Benoit Schaller
Inselspital, Universitätsspital Bern
117 PUBLICATIONS **3,315** CITATIONS

SEE PROFILE

Yufeng Zhang
Wuhan University
304 PUBLICATIONS **14,142** CITATIONS

SEE PROFILE

Anton Sculean
University of Bern
750 PUBLICATIONS **32,368** CITATIONS

SEE PROFILE

All content following this page was uploaded by Richard J Miron on 09 August 2020.

The user has requested enhancement of the downloaded file.

Taylor & Francis
Taylor & Francis Group

Platelets

ISSN: 0953-7104 (Print) 1369-1635 (Online) Journal homepage: https://www.tandfonline.com/loi/iplt20

Histological comparison of Platelet rich fibrin clots prepared by fixed-angle versus horizontal centrifugation

Masako Fujioka-Kobayashi, Michihide Kono, Hiroki Katagiri, Benoit Schaller, Yufeng Zhang, Anton Sculean & Richard J. Miron

To cite this article: Masako Fujioka-Kobayashi, Michihide Kono, Hiroki Katagiri, Benoit Schaller, Yufeng Zhang, Anton Sculean & Richard J. Miron (2020): Histological comparison of Platelet rich fibrin clots prepared by fixed-angle versus horizontal centrifugation, Platelets, DOI: 10.1080/09537104.2020.1754382

To link to this article: https://doi.org/10.1080/09537104.2020.1754382

Published online: 18 Apr 2020.

Submit your article to this journal

Article views: 4

View related articles

View Crossmark data

Full Terms & Conditions of access and use can be found at
https://www.tandfonline.com/action/journalInformation?journalCode=iplt20

http://www.tandfonline.com/iplt
ISSN: 0953-7104 (print), 1369-1635 (electronic)

platelets

Platelets, Early Online: 1–7
© 2020 Taylor & Francis Group, LLC. DOI: https://doi.org/10.1080/09537104.2020.1754382

Taylor & Francis
Taylor & Francis Group

ARTICLE

Histological comparison of Platelet rich fibrin clots prepared by fixed-angle versus horizontal centrifugation

Masako Fujioka-Kobayashi[1], Michihide Kono[1,2], Hiroki Katagiri[1,3], Benoit Schaller[1], Yufeng Zhang[4], Anton Sculean[5], & Richard J. Miron[5]

[1]Department of Cranio-Maxillofacial Surgery, Inselspital, Bern University Hospital, University of Bern, Bern, Switzerland, [2]Department of Oral and Maxillofacial Surgery, Tokyo Medical University, Tokyo, Japan, [3]Advanced Research Center, School of Life Dentistry at Niigata, The Nippon Dental University, Niigata, Japan, [4]Department of Oral Implantology, University of Wuhan, Wuhan, China, and [5]Department of Periodontology, University of Bern, Bern, Switzerland

Abstract

Platelet-rich fibrin (PRF) is prepared from whole blood without any exogenous coagulation factors. Several preparation methods have now been introduced, particularly with differences in centrifugation parameters including g-force and time to improve their regenerative potential. Nevertheless, the centrifugation systems have not yet been clearly investigated for their influences on the PRF clot properties. The aim of the present study was to visually and histologically characterize the cell separation manner and blood cell localization on the whole PRF clots prepared by two different centrifugation system, fixed-angle and horizontal centrifugation. Leukocyte- and platelet-rich fibrin (L-PRF) was prepared on a fixed-angle centrifuge machine (IntraSpin, Intra-Lock, FL, USA) at 2700 rpm (~400 g at the RCF-clot; ~700 g at the RCF-max) for 12 min. The PRF prepared by horizontal centrifugation was prepared on a horizontal centrifugation (H-PRF) (Eppendorf 5702, Eppendorf, Germany) at 700 g at the RCF-max for 8 min. The cell morphology and localization were observed on the surface of PRF clots by scanning electron microscopy (SEM) and histologically by transaxial frozen sections by means of a film method. L-PRF clots demonstrated a sloped separation between the upper plasma and the bottom red blood cell (RBC) layers according to the angle of the rotor. Red dots were often observed on the distal walls of the tubes in the upper layers, consisting of aggregations of RBCs, leukocytes and platelets by SEM and histology. Clots produced on the horizontal centrifuge showed much smoother cell layer distribution/separation along the tube surfaces when compared to L-PRF. Horizontal centrifugation also demonstrated more evenly distributed platelets throughout the PRF clots when compared to L-PRF that gathered the majority of cells along the distal tube surface or within the buffy-coat region. In summary, it was found that horizontal centrifugation resulted in a more uniform blood cell separation of PRF clots when compared to the accumulation of cells gathered along the distal tube surfaces produced prepared by fixed-angle centrifugation. Future research is needed to evaluate the benefit of horizontal centrifugation in clinical practice.

Keywords

A-PRF, fibrin, I-PRF, platelet-rich fibrin

History

Received 6 January 2020
Revised 19 March 2020
Accepted 26 March 2020
Published online 20 April 2020

Introduction

The use of autologous platelet concentrates has gained tremendous momentum in recent years as a modality to stimulate tissue regeneration [1–3]. Platelet rich plasma (PRP) was a first-generation platelet concentrate with use of anti-coagulants that favored up to a 6–8 fold increase in platelet concentrations [4–6]. Early experiments revealed the ability for several key growth factors found in blood including platelet-derived growth factor (PDGF), transforming growth factor β1 (TGF-β1), and vascular endothelial growth factor (VEGF) to be significantly expressed in higher levels when compared to whole blood favoring the modulation of tissue repair and wound healing [7–12].

PRP has since been successfully combined with various biomaterials including collagen membranes and bone grafting materials to improve their tissue integration [13–18]. Despite its widespread use, one of the main reported drawbacks of PRP included its use of anti-coagulants, an event that interferes with the natural wound healing process [19,20]. More recently, platelet rich fibrin (PRF) was proposed as a method to concentrate cells from whole blood without the use of anti-coagulants [21,22]. PRF involves the formation of a fibrin clot following centrifugation and may be utilized as a regenerative agent with a concentration of host platelets and leukocytes as well as autologous growth factors.

For years, production of PRF has been prepared using fixed-angle centrifugation yet most scientific laboratories as well as medical centrifuges utilize horizontal swing-out bucket rotors owing to their better ability to separate layers based on density. Interestingly the majority of centrifuges that are commercially

Correspondence: Richard J. Miron Department of Periodontology, University of Bern, Bern, Switzerland. E-mail: Richard.miron@zmk.unibe.ch

available for the production of PRF are fixed-angle centrifugation systems that are typically utilized for pelleting samples to the bottom of centrifugation tubes and not necessarily efficient at separating cell layers effectively.

Recently, our research group demonstrated via a novel quantification method of PRF-based matrices that PRF produced via horizontal centrifugation led to a greater yield and concentration of platelets and leukocytes when compared to commonly utilized fixed-angle centrifuges[23]. Furthermore, more recently it was shown that PRF produced via fixed-angle centrifugation accumulated the majority of cells on the distal (back of tube wall) surfaces with uneven distribution of cell types throughout the layers[24]. To date however, little data exists comparing the visual and histological differences between PRF clots produced on both centrifugation systems. Furthermore, difficulty exists previously with technically cutting large samples embedded in paraffin, however the film transfer methods [25] was developed to enable the preparation of sections from large samples without shrinkage. The aim of the present study was to characterize by visual, scanning electron microscopy (SEM) as well as histology the PRF clots produced on fixed-angle versus horizontal centrifugation and assess differences in cell layer separation.

Materials and Methods

Preparation of PRF Clots

Blood samples were collected from 4 volunteer donors who gave informed consent, and the blood was then processed for PRF clots preparation. All procedures performed in this study involving human participants were performed in accordance with the ethical standards of the institutional and/or national research committee and with the 1964 Declaration of Helsinki and its later amendments or comparable ethical standards. No internal review board (IRB) was required for this study because the human samples were not identified, as previously described [26]. All blood samples were obtained from members of our laboratory between the ages of 30 and 60. For L-PRF preparation, 2 tubes of 10 mL of whole blood without anticoagulants in plain glass tubes (Chixin Biotech, Wuhan, China) were centrifuged at 2700 rpm (~400 g at the RCF-clot and ~700 g at the RCF-max) for 12 minutes on a fixed-angled centrifuge machine (Intra-Spin system, Intra-Lock, Boca Raton, FL, USA). Horizontal centrifugation (H-PRF) was carried out using 2 tubes of 10 mL of blood in glass tubes (Chixin Biotech) using at 700 g for 8 minute protocol (5702 Eppendorf, Hamburg, Germany). The time required for centrifugation carried out on a horizontal requires 2/3 of that of a fixed-angle centrifuge (https://druckerdiagnostics.com/horizontal-vs-fixed-angle/). Therefore, the 12 minute protocol utilized in this study on the fixed-angle centrifuge equates perfectly to an 8 minute protocol utilized on a horizontal centrifuge at the same RCF value (both 700 g).

Scanning Electron Microscope (SEM) Imaging

The PRF clots were fixed at 37°C for 1 h, then at 4°C overnight using 2.5% glutaraldehyde (Merck, Darmstadt, Germany) in 0.1 M sodium cacodylate buffer (pH 7.4; Merck). Thereafter, the specimens were dehydrated through an ascending ethanol series, dried in hexamethyldisilazane (Sigma). Dried specimens were mounted onto aluminum stubs by means of double-adhesive conductive tabs (Portmann Instruments, Biel-Benken, Switzerland). The specimens were then sputter-coated with 15 nm of platinum in a CCU-010 sputtering device (Safematic, Bad Ragaz, Switzerland) and stored in a desiccator. SEM images were obtained with a DSM 982 Gemini digital field emission SEM (Zeiss, Oberkochen, Germany) at an accelerating voltage of 5 kV and a working distance of 7 mm.

Histological Sample Preparation

The PRF clot specimens were fixed in 4% formaldehyde in phosphate-buffered saline (PBS) on ice while shaking longitudinally for 24 hours and embedded in Polyfreeze tissue freezing medium (Sigma, St. Louis, MO, USA) after sucrose equilibration. The frozen specimens were sectioned into 8-μm-thick slices in the chamber of a cryomicrotome (Hyrax C60, Zeiss, Oberkochen, Germany) with an adhesive film (Cryofilm Type 2 C(16UF), Section-Lab, Hiroshima, Japan) using Kawamoto's film transfer method[25]. The sections were stained with hematoxylin (Section-Lab). The images were captured with a digital microscope (VHX-6000, Keyence, Osaka, Japan).

Results

Macroscopic Observation of L-PRF and H-PRF (Figure 1)

The PRF clots were prepared on two different centrifugation systems, namely fixed-angle for the production of L-PRF and horizontal centrifugation for the production of H-PRF. The two PRF clots showed obvious differences in their layer separation. L-PRF demonstrated a sloped or 'angled' separation of plasma and red blood cell (RBC) layer separation owing to the angle of the rotor whereas PRF produced by horizontal centrifugation produced a clean distinct layer separation (Figure 1). Interestingly, many red dots were observed on the distal surface of centrifugation tubes produced using the fixed-angle L-PRF protocols (Figure 1b).

Microscopic and Histological Observation of L-PRF and H-PRF (Figures 2-5)

PRF clots were further investigated by SEM and histological assessment for cell distribution and surface configurations (Figures 2–5). A previously described protocol using frozen sections and film technique was selected in order to accurately orient the PRF clots. It was observed that three distinct typical patterns were observed on the distal walls of L-PRF clots, including RBC clusters on the smooth or wavy fibrin clot surfaces, whereas clusters of leukocytes, platelets and crushed RBCs were occasionally found (Figure 2b-d). Histological observation further confirmed these two pattern-types (Figure 4b and c). The border between the plasma and RBC layers included a more dense fibrin networks covered with many blood cells (Figure 2e). Many leukocytes were found at this layer (Figure 4d).

Within H-PRF clots, two typical patterns were observed on the surface, including fewer blood cells on the smooth clot surfaces, with more found located on the rough surfaces (Figure 3b and c). The PRF clots included mainly abundant platelets within the clots with a few clusters located on the actual clot surface (Figure 5b and c). The border between the plasma and RBC layers included a dense fibrin network with many leukocytes (Figures 2d and e, 5d). Interestingly, aggregated clusters of platelets with leukocytes was found in both L-PRF and H-PRF within the RBC layer approximately 5-mm below from the precise separation typically referred to as the red 'buffy-coat' zone (Figures 4e, 5e).

Discussion

The present article investigated for the first time PRF clots produced by either fixed-angle and horizontal centrifugation utilizing SEM as well as macroscopic and microscopic evaluations. In general, it was observed that the majority of cells were located on the distal surface of L-PRF clots whereas cells were found more evenly distributed when H-PRF protocols were utilized. These findings are in accordance with previous work by our

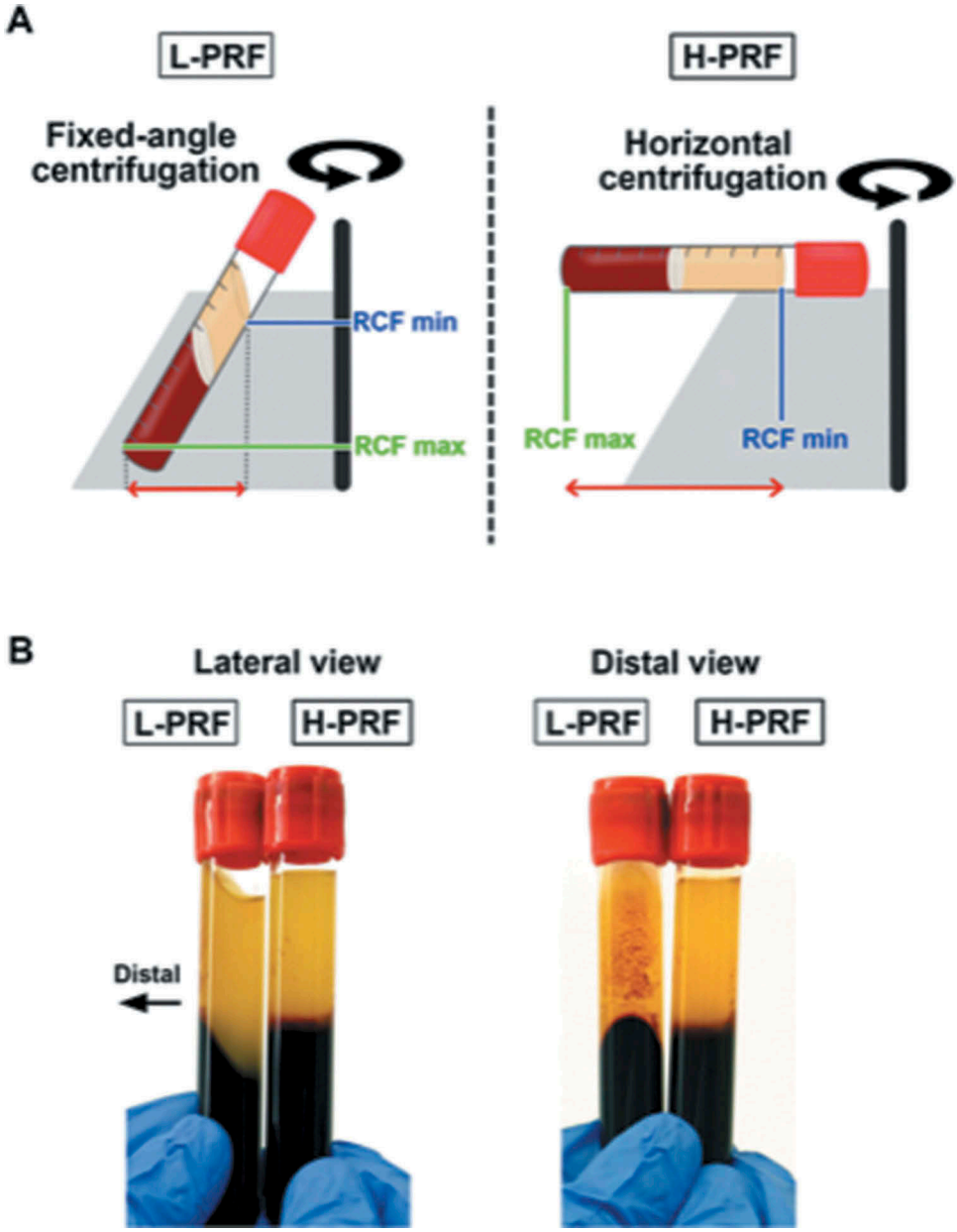

Figure 1. (a) Illustration of PRF produced via fixed-angle (L-PRF) and horizontal centrifugation (H-PRF). (b) Visual representation of layer separation following either L-PRF or H-PRF protocols. L-PRF clots are prepared with a sloped shape and multiple red dots often observed on the distal surface of PRF tubes while H-PRF was prepared with a horizontal layer separation between the upper plasma and lower red corpuscule layer.

group demonstrating that horizontal centrifugation of PRF accumulated up to 4 times more cells (especially leukocytes) within the plasma layers when compared to fixed-angle centrifugation [27]. Thus, the aim of the present study was to further investigate utilizing histological assessment differences between fixed-angle and horizontal centrifugation of PRF. A very recent study by Takahashi et al. (2019) demonstrated that most cells accumulated on the distal surface of PRF clots when various fixed-angle centrifugation systems were utilized (no comparison to horizontal centrifugation was performed)[24]. Within the present study, our group aimed to histologically evaluate for the first time that horizontal centrifugation of PRF led to more cells evenly distributed throughout the PRF clots when compared to fixed-angle centrifugation. Based on the various uses of PRF in clinical practice, membrane more evenly distributed in cells[24].

One interesting finding in the present study was the significant number of cell clusters located on the distal surface of L-PRF clots produced on fixed-angle centrifugation (Figure 1b). It was also interesting to note that utilizing either centrifugation system, the clots tended to be composed of smooth surfaces near the upper portion of the PRF clot (Figure 2b, 3b) whereas had a more roughened and fibrillar shape near the buffy coat region (Figure 2e, 3d). Noteworthy, most publications to date demonstrating PRF clots within scientific journals typically select images demonstrating a fibrillar image with entrapment of cells however, we note within the present study that in fact this represents only a small percentage of the overall appearance of the PRF clots.

Thereafter, histological assessment was utilized to investigate cell distribution within PRF clots utilizing either L-PRF or H-PRF protocols (Figure 4, 5). By macroscopic observation, it was found that L-PRF protocols produced an angle separation of plasma and RBC layers whereas H-PRF produced an even horizontal separation. Cell separation from both groups demonstrated that the majority of cells were located at the distal surface utilizing L-PRF protocols whereas cells were more evenly distributed

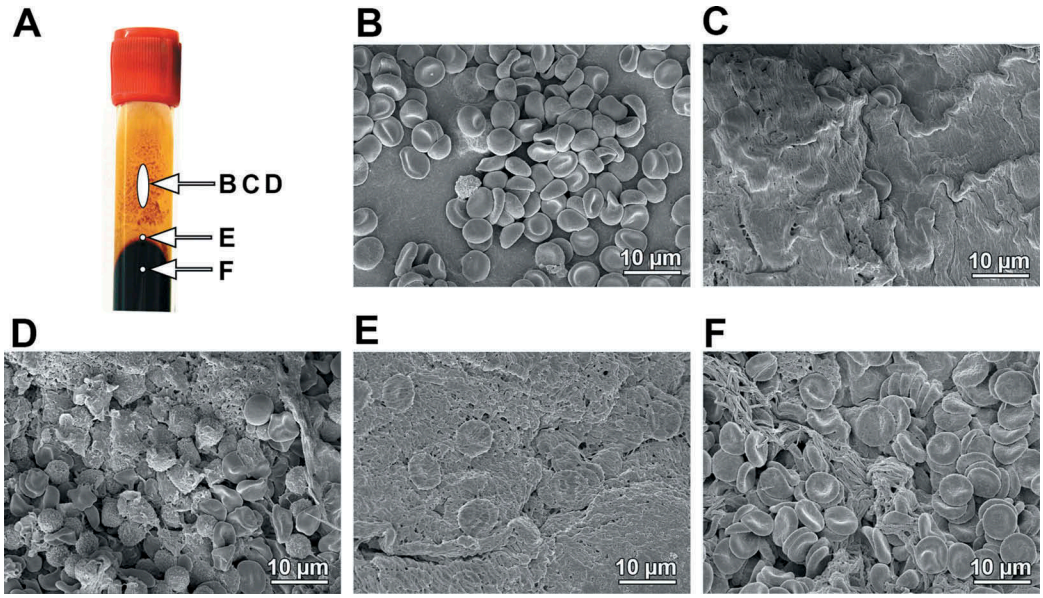

Figure 2. SEM images of the distal surface of PRF clots prepared utilizing the L-PRF protocol. (a) The described areas observed by SEM. The L-PRF clots surfaces showed typically three types as shown in B-D. (b) The clusters of red blood cells (RBCs) were observed overlaying a smooth clot surface. (c) The wavy surface was observed including RBCs. (d) The rough surface included leukocytes, platelets and crushed RBCs. (e) The dense fibrin networks were observed including RBCs at the border between the yellow plasma and red RBC layers. (f) Many RBCs were observed within a fibrin network in the RBC layer.

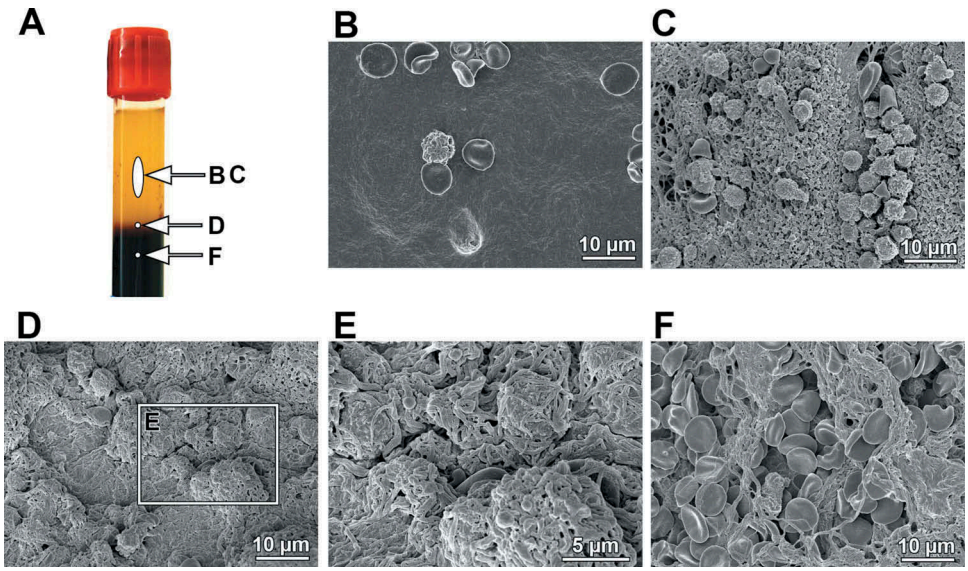

Figure 3. SEM images of the distal surface of PRF clots prepared utilizing the H-PRF protocol. (a) The described areas observed by SEM. The H-PRF clots surfaces showed typical two types shown in b and c. A smooth clot surface was observed in pattern (b) and a rough surface were less frequently observed in pattern (c). (b) Few leukocytes and RBCs were observed on the smooth surfaces. (c) The rough surfaces included leukocytes, platelets and RBCs. (d, e) The fibrin networks twisted around the leukocytes with platelets at the border between the yellow plasma and red RBC layers. (f) Many RBCs were observed within a fibrin network in the RBC layer.

following H-PRF preparation (Figure 6). This is particularly of significant relevance when the PRF clots are flattened and utilized as thin membranes for regenerative purposes such as covering various defects or underneath suture closure sites (Figure 6).

In general, it is easier to accumulate platelets in the upper plasma layer since they are lighter (less dense) when compared to white blood cells. For this reason, platelet distribution within the upper layers is much easier to achieve when compared to leukocytes which are much closer in cell density to red blood cells. Leukocytes are much more difficult to accumulate within the PRF matrix, and this is especially true when utilizin fixed-angle centrifugation where the number of RBCs outnumber WBCs typically 1000:1 and the majority of cells accumulate along the back distal surface of PRF tubes where they generally cannot separate accurately[28]. Furthermore, our group previously demonstrated that while platelets could be increased in yield by ~20% on horizontal centrifugation versus fixed angle, leukocytes demonstrated a pronounced and marked increase in comparison (closer to 400%)[28]. White blood cells in particular are important during wound healing, especially during biomaterial integration and tissue formation [29–33].

Furthermore, it is important to note that in either protocol, the majority of cells were located within the buffy coat region. Interestingly, some platelet clusters with containment of leukocytes

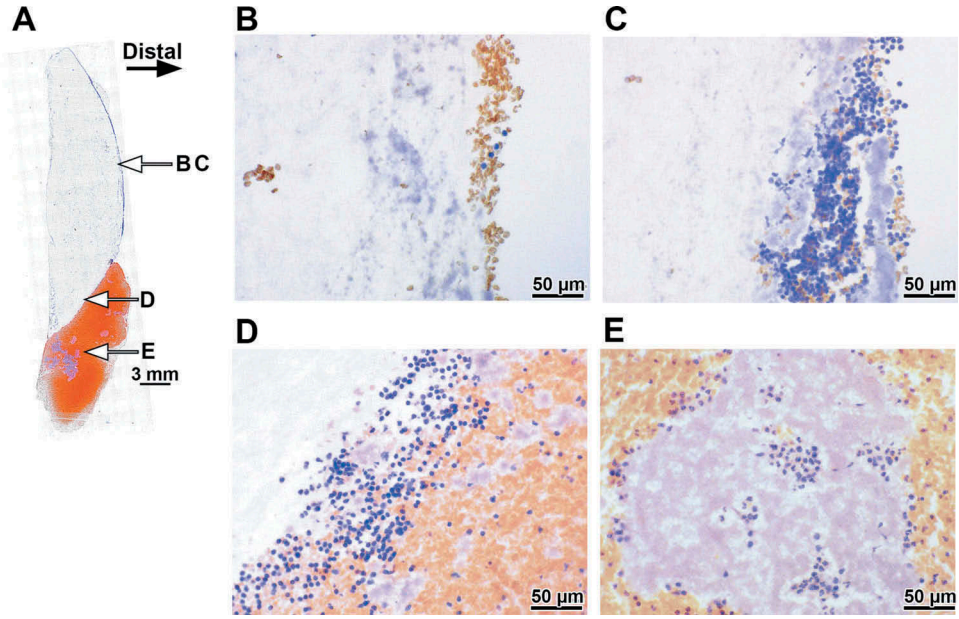

Figure 4. Histological observation of the frozen section of L-PRF sectioned trans-axially. (a) The panoramic view of the sections from the whole PRF clot including the RBC layer stained with hematoxylin. The L-PRF clots and RBC layer were separated by a fixed-angle. The distal wall showed two typical patterns shown in b and c. (b) A lots of RBCs with few leukocytes were located on fibrin networks on the distal surface. (c) The aggregated cluster consisting of platelets, leukocytes and RBCs were occasionally observed. (d) Many leukocytes were located at the border between the PRF clot and the RBC layer. (e) The aggregated clusters of cells containing leukocytes were occasionally observed within the RBC layer within the red buffy coat zone.

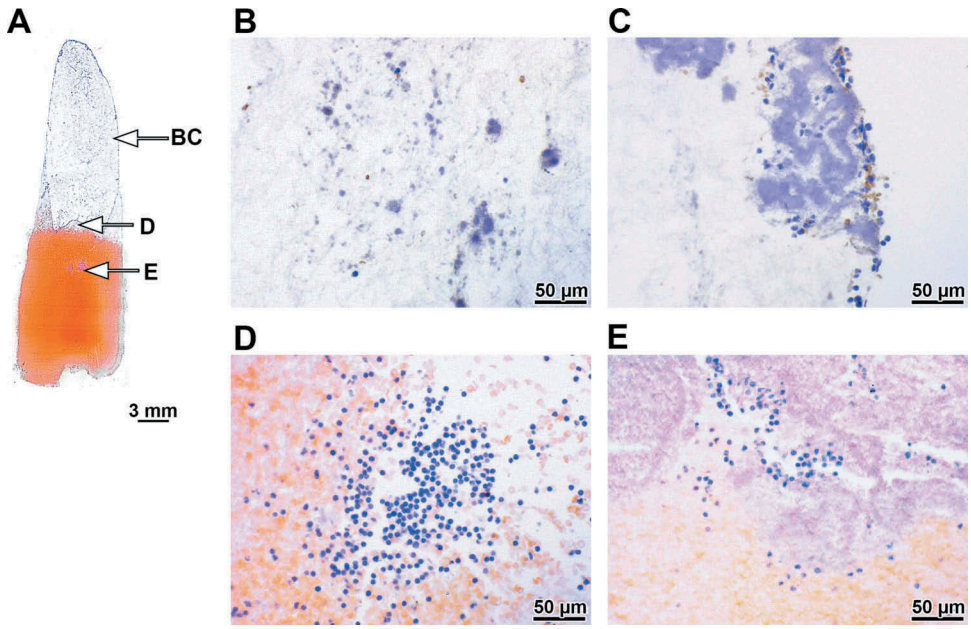

Figure 5. Histological observation of the frozen section of H-PRF sectioned trans-axially. (a) The panoramic view of the sections from the whole PRF clot including the RBC layer stained with hematoxylin. The H-PRF clots and RBC layers were separated evenly and horizontally with no obvious accumulation of cells on the distal surface. The clots showed two typical patterns shown in b and c. (b) The fibrin networks were observed in the clots with many platelets with few leukocytes/RBCs. (c) The aggregated cluster consisting of leukocytes and a few RBCs were occasionally observed. (d) Many leukocytes were located at the border between the clots and RBC layer. () The aggregated clusters of cells containing leukocytes were occasionally observed in the RBC layer within the red buffy coat zone.

were also found sunk within the RBC layer located within 5-mm below the yellow plasma layer (Figures 4e, 5e). Based on these findings, it may be recommended that this specific red 'buffy coat' zone is also quite rich in leukocytes and platelets. Recently, a study by Thanasrisuebwong et al investigated the influence of fractionation methods on physical and biological properties of liquid PRF and found that the inclusion of the red buffy coat zone significantly increased growth factor release from liquid PRF[34]. Future research investigating specifically the quantity of the buffy coat zone including vs excluding the red zone is of great clinical interest requiring further optimization and clinical guidelines.

In conclusion it was demonstrated that L-PRF clots produced via fixed-angled centrifugation generated an angled separation between the upper plasma and lower RBC layer as a result of

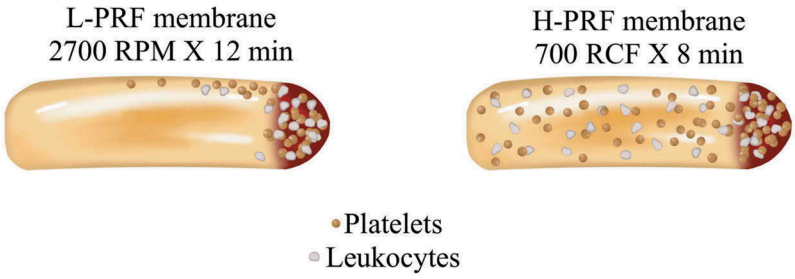

Figure 6. Graphical figure demonstrating cell distribution within PRF when centrifugation was carried out either by fixed-angle or horizontal centrifugation. Note that the majority of cells following L-PRF protocol are found along the back distal surface of PRF clots as well as primarily contained within the buffy coat layer. A more even distribution of cells was observed when horizontal centrifugation was utilized.

the angle of the rotor. Red dots were frequently observed on the distal surfaces of L-PRF clots and this was also observed more frequently via either SEM analysis or histological assessment. The H-PRF clots produced on a horizontal centrifuge showed much more evenly distributed cell layers when compared to L-PRF. In both protocols, a higher number of platelets and especially leukocytes were located within the buffy coat region up to 5 mm within the red buffy coat region. Based on the findings from the present study, future research is now needed to evaluate the benefit of horizontal centrifugation for various clinical procedures in medicine and dentistry.

Disclosure Statement

All other authors declare no conflict of interest.

Funding

None reported.

Author contributions

MFK, MK, and HK performed the experiments and histological analysis. MFK, MK, and HK performed the scanning electron microscopy work. MFK, BS, YZ, AS and RJM designed the experiments. MFK and RJM drafted the manuscript. All authors participated in the critical review of the study. All authors read, corrected and approved the final manuscript.

References

1. Miron RJ, Zucchelli G, Pikos MA, Salama M, Lee S, Guillemette V, Fujioka-Kobayashi M, Bishara M, Zhang Y. Wang HL and others. Use of platelet-rich fibrin in regenerative dentistry: a systematic review. Clin Oral Investig 2017;21(6):1913–1927. DOI:10.1007/s00784-017-2133-z
2. Castro AB, Meschi N, Temmerman A, Pinto N, Lambrechts P, Teughels W, Quirynen MJJocp. Regenerative potential of leucocyte-and platelet-rich fibrin. Part A: intra-bony defects, furcation defects and periodontal plastic surgery. A Syst Rev Meta-anal 2017;44(1):67–82.
3. Castro AB, Meschi N, Temmerman A, Pinto N, Lambrechts P, Teughels W, Quirynen M. Regenerative potential of leucocyte-and platelet-rich fibrin. Part B: sinus floor elevation, alveolar ridge preservation and implant therapy. A Syst Rev 2017;44(2):225–234.
4. Marx RE. Platelet-rich plasma (PRP): what is PRP and what is not PRP? Implant Dent 2001;10(4):225–228. DOI:10.1097/00008505-200110000-00002
5. Marx RE. Platelet-rich plasma: evidence to support its use. J Oral Maxillofac Surg 2004;62(4):489–496. DOI:10.1016/j.joms.2003.12.003
6. Marx RE, Carlson ER, Eichstaedt RM, Schimmele SR, Strauss JE, Georgeff KR. Platelet-rich plasma: growth factor enhancement for bone grafts. Oral Surg Oral Med Oral Pathol Oral Radiol Endod 1998;85(6):638–646. DOI:10.1016/S1079-2104(98)90029-4
7. I, Alvarez-Juarez P. The efficacy of platelet-rich plasma injection in the management of hip osteoarthritis: a systematic review protocol. Musculoskeletal Care 2016;14(2):121–5. doi:10.1002/msc.1115.
8. F, Veronesi F, Maglio MDella Bella E. New and emerging strategies in platelet-rich plasma application in musculoskeletal regenerative procedures: general overview on still open questions and outlook. Biomed Res Int. 2015;2015:846045. doi:10.1155/2015/846045.
9. Albanese A, Licata ME, Polizzi B, Campisi G. Platelet-rich plasma (PRP) in dental and oral surgery: from the wound healing to bone regeneration. Immun Ageing 2013;10(1):23. DOI:10.1186/1742-4933-10-23
10. Dohan Ehrenfest DM, Andia I, Zumstein MA, Zhang CQ, Pinto NR, Bielecki T. Classification of platelet concentrates (Platelet-Rich Plasma-PRP, Platelet-Rich Fibrin-PRF) for topical and infiltrative use in orthopedic and sports medicine: current consensus, clinical implications and perspectives. Muscles Ligaments Tendons J 2014;4(1):3–9. DOI:10.32098/mltj.01.2014.02
11. Maney P, Amornporncharoen M, Palaiologou A. Applications of plasma rich in growth factors (PRGF) in dental surgery: a review. J West Soc Periodontol Periodontal Abstr 2013;61(4):99–104.
12. S, Doraiswamy J, Malaiappan S, Varghese SSDel Fabbro M. Additive effect of autologous platelet concentrates in treatment of intrabony defects: a systematic review and meta-analysis. J Investig Clin Dent. 2016;7(1):13–26. doi:10.1111/jicd.12117.
13. Dori F, Arweiler N, Huszar T, Gera I, Miron RJ, Sculean A. Five-year results evaluating the effects of platelet-rich plasma on the healing of intrabony defects treated with enamel matrix derivative and natural bone mineral. J Periodontol 2013;84(11):1546–1555. DOI:10.1902/jop.2012.120238
14. Ozdemir B, Okte E. Treatment of intrabony defects with beta-tricalciumphosphate alone and in combination with platelet-rich plasma. J Biomed Mater Res B Appl Biomater 2012;100(4):976–983. DOI:10.1002/jbm.b.32660
15. Yilmaz S, Kabadayi C, Ipci SD, Cakar G, Kuru B. Treatment of intrabony periodontal defects with platelet-rich plasma versus platelet-poor plasma combined with a bovine-derived xenograft: a controlled clinical trial. J Periodontol 2011;82(6):837–844. DOI:10.1902/jop.2010.100503
16. Camargo PM, Lekovic V, Weinlaender M, Divnic-Resnik T, Pavlovic M, Kenney EB. A surgical reentry study on the influence of platelet-rich plasma in enhancing the regenerative effects of bovine porous bone mineral and guided tissue regeneration in the treatment of intrabony defects in humans. J Periodontol 2009;80(6):915–923. DOI:10.1902/jop.2009.080600
17. Camargo PM, Lekovic V, Weinlaender M, Vasilic N, Madzarevic M, Kenney EB. A reentry study on the use of bovine porous bone mineral, GTR, and platelet-rich plasma in the regenerative treatment of intrabony defects in humans. Int J Periodontics Restorative Dent 2005;25(1):49–59.
18. Yassibag-Berkman Z, Tuncer O, Subasioglu T, Kantarci A. Combined use of platelet-rich plasma and bone grafting with or without guided tissue regeneration in the treatment of anterior interproximal defects. J Periodontol 2007;78(5):801–809. DOI:10.1902/jop.2007.060318
19. Del Corso M, Vervelle A, Simonpieri A, Jimbo R, Inchingolo F, Sammartino G, Dohan Ehrenfest DM. Current knowledge and perspectives for the use of platelet-rich plasma (PRP) and platelet-rich fibrin (PRF) in oral and maxillofacial surgery part 1: periodontal and dentoalveolar surgery. Curr Pharm Biotechnol 2012;13(7):1207–1230. DOI:10.2174/138920112800624391
20. Simonpieri A, Del Corso M, Vervelle A, Jimbo R, Inchingolo F, Sammartino G, Dohan Ehrenfest DM. Current knowledge and perspectives for the use of platelet-rich plasma (PRP) and platelet-rich fibrin (PRF) in oral and maxillofacial surgery part 2: bone graft, implant and reconstructive surgery. Curr Pharm Biotechnol 2012;13(7):1231–1256. DOI:10.2174/138920112800624472

21. Choukroun J, Diss A, Simonpieri A, Girard MO, Schoeffler C, Dohan SL, Dohan AJ, Mouhyi J, Dohan DM. Platelet-rich fibrin (PRF): a second-generation platelet concentrate. Part V: histologic evaluations of PRF effects on bone allograft maturation in sinus lift. Oral Surg Oral Med Oral Pathol Oral Radiol Endod 2006;101 (3):299–303. DOI:10.1016/j.tripleo.2005.07.012
22. Dohan DM, Choukroun J, Diss A, Dohan SL, Dohan AJ, Mouhyi J, Gogly B. Platelet-rich fibrin (PRF): a second-generation platelet concentrate. Part II: platelet-related biologic features. Oral Surg Oral Med Oral Pathol Oral Radiol Endod 2006;101(3):e45–50. DOI:10.1016/j.tripleo.2005.07.009
23. Miron RJ, Chai J, Zheng S, Feng M, Sculean A, Zhang Y. A novel method for evaluating and quantifying cell types in platelet rich fibrin and an introduction to horizontal centrifugation. J Biomed Mater Res A 2019;107(10):2257–2271.
24. A, Tsujino T, Yamaguchi S, Isobe K, Watanabe T, Kitamura Y, Okuda K, Nakata KKawase T. Distribution of platelets, transforming growth factor-beta1, platelet-derived growth factor-bb, vascular endothelial growth factor and matrix metalloprotease-9 in advanced platelet-rich fibrin and concentrated growth factor matrices. J Investig Clin Dent. 2019;10(4):e12458. doi:10.1111/jicd.12458.
25. T, Kawamoto K. Preparation of thin frozen sections from nonfixed and undecalcified hard tissues using kawamot's film method (2012). Skeletal Dev Repair: Springer, Methods Mol Biol. 2014;1130:149–164. doi:10.1007/978-1-62703-989-5_11.
26. RJ, Fujioka-Kobayashi M, Hernandez M, Kandalam U, Zhang Y, Ghanaati SChoukroun J. Injectable platelet rich fibrin (i-prf): opportunities in regenerative dentistry? clin oral investig. 2017;21 (8):2619–2627. doi:10.1007/s00784-017-2063-9.
27. Miron RJ, Chai J, Zheng S, Feng M, Sculean A, Zhang Y. A novel method for evaluating and quantifying cell types in platelet rich fibrin and an introduction to horizontal centrifugation. J Biomed Mater Res A 2019.
28. Miron RJ, Chai J, Zheng S, Feng M, Sculean A, Zhang Y. A novel method for evaluating and quantifying cell types in platelet rich fibrin and an introduction to horizontal centrifugation. J Biomed Mater Res Part A 2019;107(10):2257–2271.
29. Miron RJ, Bosshardt DD. OsteoMacs: key players around bone biomaterials. Biomaterials 2016;82:1–19. DOI:10.1016/j.biomaterials.2015.12.017
30. Chang MK, Raggatt LJ, Alexander KA, Kuliwaba JS, Fazzalari NL, Schroder K, Maylin ER, Ripoll VM, Hume DA, Pettit AR. Osteal tissue macrophages are intercalated throughout human and mouse bone lining tissues and regulate osteoblast function in vitro and in vivo. J Immunol 2008;181(2):1232–1244. DOI:10.4049/jimmunol.181.2.1232
31. Batoon L, Millard SM, Raggatt LJ, Pettit AR. Osteomacs and bone regeneration. Curr Osteoporos Rep 2017;15(4):385–395. DOI:10.1007/s11914-017-0384-x
32. Sinder BP, Pettit AR, McCauley LK. Macrophages: their emerging roles in bone. J Bone Miner Res 2015;30(12):2140–2149. DOI:10.1002/jbmr.2735
33. Winkler IG, Sims NA, Pettit AR, Barbier V, Nowlan B, Helwani F, Poulton IJ, van Rooijen N, Alexander KA. Raggatt LJ and others. Bone marrow macrophages maintain hematopoietic stem cell (HSC) niches and their depletion mobilizes HSCs. Blood 2010;116 (23):4815–4828. DOI:10.1182/blood-2009-11-253534
34. Thanasrisuebwong P, Surarit R, Bencharit S, Ruangsawasdi N. Influence of fractionation methods on physical and biological properties of injectable platelet-rich fibrin: an exploratory study. Int J Mol Sci 2019;20(7). DOI:10.3390/ijms20071657

View publication stats